

A HAND BOOK OF LOWER LIMB NERVE BLOCKS

From the author's desk

Regional Anaesthesia is here to stay. Overcoming various hurdles in its history of development, it now is accepted as a very safe modality of anaesthesia. It has the potential to make impossible surgeries probable.

The foray of the Anaesthesiologist into Pain relief, both acute and chronic necessitated the development of new means that offer pain relief without compromising the physiological parameters of the patient. In these clinical scenarios nerve blocks are a necessary tool in the armamentarium of the anaesthesiologist.

As I journey on my path to popularize the art of regional anaesthesia, I have attempted to demystify blocks of the lower limb. This is an additional to my attempts at simplifying upper limb blocks and segmental epidurals.

Before I get to the job, I wish to re-assert that understanding anatomy, physiology and pharmacology, paying attention to monitoring and complete care, assessing patients adequately and paying attention to the demands of the patient remain as always the primary requirement for the success of a regional anaesthetic technique.

Dr.R.Silamban

INTRODUCTION

Most anaesthesiologists are comfortable with upper extremity regional block than the lower extremity regional block. This is because the surgery in the lower limb can be comfortably done with neuraxial blocks whenever regional anaesthesia is contemplated. Also the nerves of the lower limb are not as compactly packed like in the brachial plexus of the upper limb. The nerves enter the leg in a widespread manner farther away from each other.

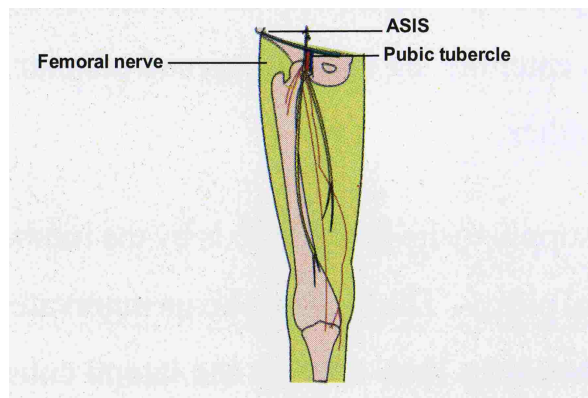
The nerve supply to the lower limb is by the lumbar plexus and lumbosacral plexus. The lumbar plexus innervates the anterior aspect of the lower limb through the lateral cutaneous nerve, femoral nerve and obturator nerve. While the lumbosacral plexus innervates the posterior aspect of the lower limb through the sciatic nerve and posterior cutaneous nerve of thigh.

In this booklet we are going to deal with some of the common lower limb nerve blocks along with illustrations.

FEMORAL NERVE BLOCK

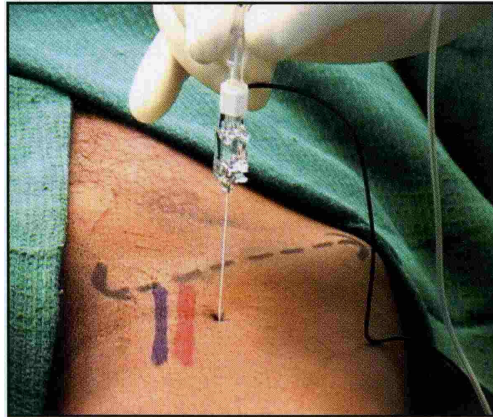
Root Value: L:2, L3, & L4

Course:: It enters the femoral triangle by passing behind the inguinal ligament to course posterolateral to the femoral artery. The nerve lies outside the femoral sheath. After coursing for about 3-4 cms it divides into anterior and posterior divisions. Anterior division mainly supplies the sartorius muscle while the posterior division innervates the three vasti muscles and rectus femoris.



Position: Supine

Site of Needle Entry: A point 2 cms below the inguinal ligament and 1cm lateral to the femoral artery.



Technique: A 4cm needle is entered at the above point perpendicular to the skin to pierce the iliopsoas fascia and fascia lata and parasthesia is elicited. If nerve locator is used the motor response depends on division of the femoral nerve that is stimulated. If the anterior division is stimulated the vasti respond. It is always better to have a motor response of the posterior division for a complete block especially if surgery is around the knee joint.

After the first injection of the drug the needle is removed and again entered into the skin from a site 1 cm lateral to the previous point and the needle is directed to lie below the femoral artery. About 8 ml of drug is injected here. This ensures the posterior division is always blocked.

Volume: 20ml

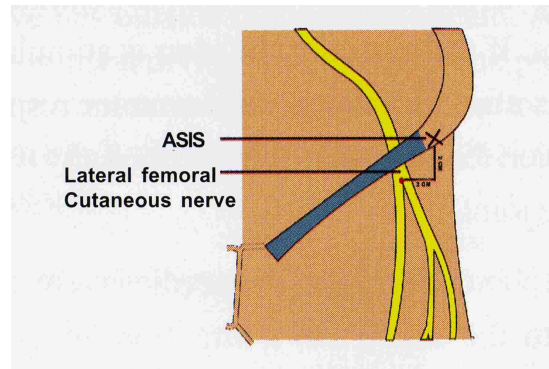
Pearls:

- In 20% of individuals the nerve divides above the inguinal ligament. In such circumstances separate block of the posterior division is very vital
- Continuous catheter can be placed here
- Very useful for acute pain relief in femur fractures.

LATERAL CUTANEOUS NERVE OF THIGH

Root Value: L2, L3

Course: Takes a very lateral course in the pelvis to come behind the lateral end of the inguinal ligament and lie beneath the fascia lata. Within 2.5cm of entering the thigh it divides into multiple small branches to supply the skin on the lateral side of thigh.



Position: Supine

Site of Needle Entry: 2cm medial and inferior to the anterior superior iliac spine

Technique: At the above point a 4cm needle is advanced perpendicular to the skin till a “pop off” is felt once the fascia lata is pierced. 8ml is given here. The needle is withdrawn above the fascia lata and additional 3 ml of drug is given here to block some cutaneous branches.

Volume: 10 to 12 ml

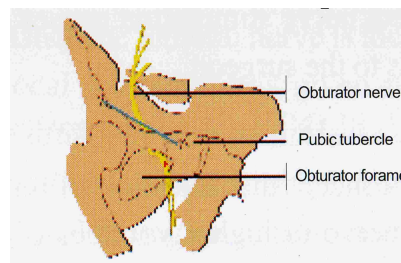
Pearls:

- Only a sensory nerve and no motor response is expected
- This nerve is most commonly spared when a three in one block is attempted

OBTURATOR NERVE BLOCK

Root Value: L2, L3 & L4

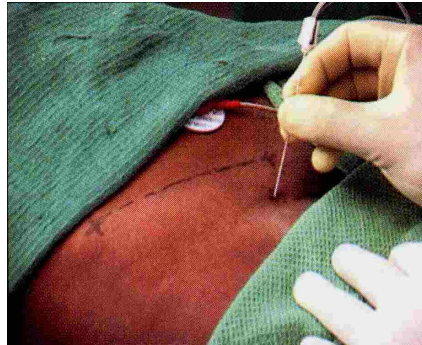
Course: Upper part of the nerve lies in the pelvis and enters the thigh by passing through the obturator foramen. Just outside the foramen it divides into anterior and posterior divisions.



They supply the adductor muscle of the thigh and also gives a small branch to the capsule of the knee joint.

Position: Supine

Site of Needle Entry: 1.5cm below and lateral to pubic tubercle.



Technique: A 10cm needle is advanced perpendicularly till the ramus of pubis is contacted. It is then withdrawn and redirected in a lateral direction to pierce the obturator membrane which is felt as a give way and parasthesia is elicited. If a nerve locator is used contractions of the adductors of the thigh is elicited. The nerve is usually located at a depth of 6-7cms from the skin.

Volume: 10 ml.

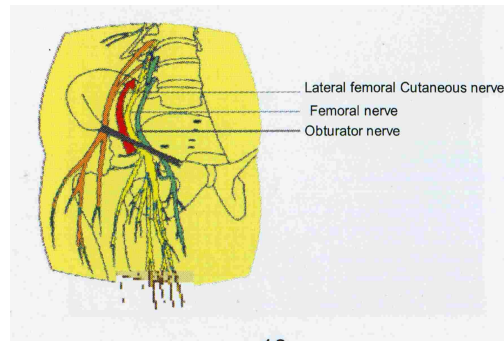
Pearls:

- As the nerve is deep, use of nerve locator is very useful
- Very useful block in transurethral resection of bladder tumour as direct nerve stimulation causes discomforting leg movements to the surgeon.

THREE IN ONE BLOCK **(Inguinal Perivascular Block)**

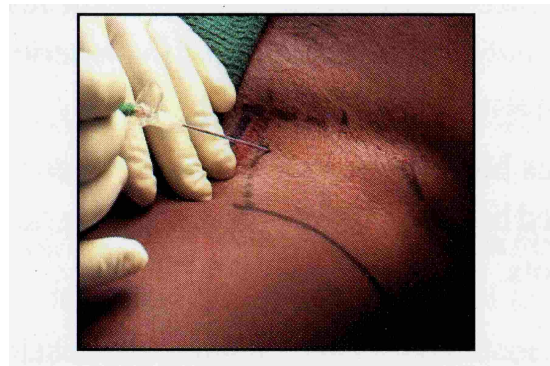
It is based on the concept that injection of local anaesthetic near the femoral nerve in higher volumes causes the local anaesthetic to track proximally along the fascial planes between the iliacus and psoas muscles to reach the lumbar plexus roots.

This blocks all the three major nerves arising from the lumbar plexus namely the lateral cutaneous nerve of thigh, the femoral nerve and the obturator nerve.



Position: Supine

Site of Needle Entry: Similar to femoral nerve block but the direction of needle entry may be about 45 degree to 60 degree to the skin especially when a continuous catheter is planned. The angulation of the needle facilitates catheter insertion.



Technique: Once the femoral nerve is located with the nerve locator the local anaesthetic is given while giving distal pressure. The drug may also be milked cephalad to facilitate travel along the iliopsoas muscle plane. Alternatively a catheter may be introduced through a suitable needle to lie within the iliopsoas muscle plane near the lumbar nerve roots as shown in the figure. Catheter is inserted for 10-15cms. The muscle plane may be expanded with local anesthetic or normal saline prior to catheter insertion.

Volume: 30-40ml

Pearls:

- All three nerves are not always reliably blocked with single needle technique.
- Lateral cutaneous nerve is often missed as it is more proximally placed and has a different nerve root origin.
- As the lumbar plexus gives contribution to the sacral plexus, spill over into the sciatic nerve territory may occur rarely. This results in a four in one nerve block.

- Motor response of the vastus muscles is elicited to ensure blockage of the posterior division, especially when surgery near the knee joint is required. The motor response of the sartorius indicates stimulation of the anterior division of the femoral nerve.
- This block becomes more predictable when the catheter is introduced between the muscle plane to lie near the lumbar nerve roots.

SCIATIC NERVE BLOCK

Largest peripheral nerve of the body

There are two common approaches

1. Classical approach of Labat
2. Anterior Approach

Root Value: L4, L5, S1, S2, S3.

Course: The roots join to form the sciatic nerve on the anterior surface of the piriformis muscle. It is formed due to the union of the following major trunks.

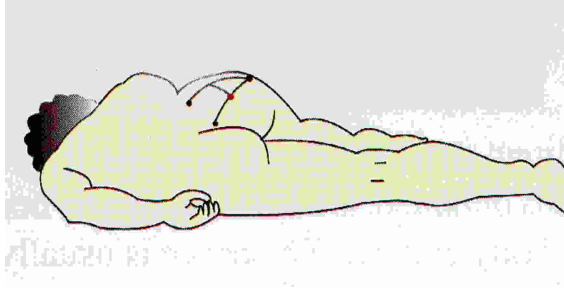
- The medial sciatic nerve is due to fusion of the ventral branches of the ventral rami of L4-S3. This is functionally the tibial nerve.
- The lateral sciatic nerve is due to fusion of the posterior branches of the ventral rami of L4S3. This is functionally the common peroneal nerve.

The nerve comes out of the pelvis through the greater sciatic foramen. Once the nerve crosses the piriformis muscle it lies anterior to gluteus maximus and posterior to obturator internus and quadriceps femoris. The nerve continues through the thigh along the posteromedial aspect of the femur to reach the popliteal fossa. In the fossa it divides into tibial and common peroneal nerve.

CLASSIC APPROACH OF LABAT

Position:

Patient is placed laterally. Side to be blocked is nondependent. Dependent leg is extended and nondependent leg is flexed to 90 degree. Heel is placed apposing the knee of the dependent leg.

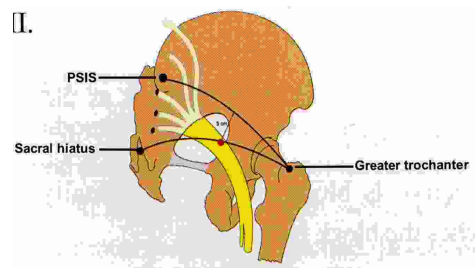


Site of Needle Entry:

Line I – From posterior superior iliac spine to greater trochanter

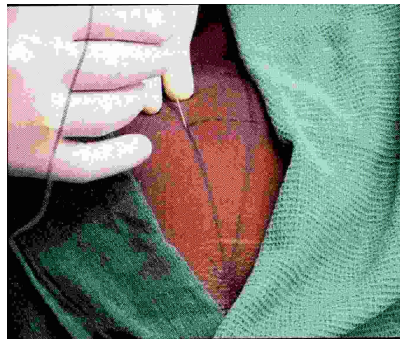
Line II – From sacral hiatus to greater trochanter

Line III – From midpoint of the Line I perpendicularly to join the Line II.



Site of needle entry is where the perpendicular line meets the second line. This point is opposite the site where the sciatic nerve comes through the greater sciatic foramen.

Technique: A 12 to 15cm needle is entered from the above point perpendicular to the skin towards an imaginary point where femoral vessels go under the inguinal ligament. If the bone is contacted before parasthesia or motor response withdraw the needle and



redirect it along the second line till parasthesia or motor response is obtained. Do not advance the needle for more than 2cm after bony contact. The nerve is usually located at a depth of 8cms in a moderately built patient.

Paresthesia is more commonly felt in the peroneal territory. The motor response to be anticipated is dorsiflexion and eversion of foot.

Volume: 15-20 ml

Pearls:

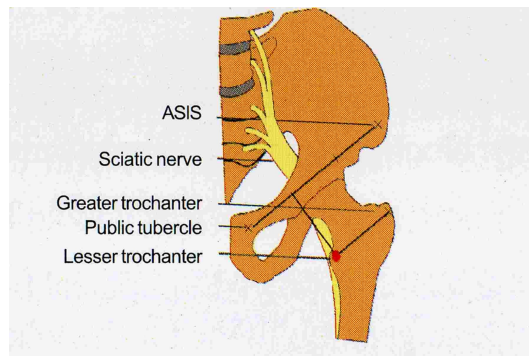
- Not very useful for traumatic patient as the position is difficult to achieve
- As the nerve is blocked more proximally of all the approaches the block is complete
- As the nerve is thicker, higher concentration of local anaesthetic is needed.
- Ideal site for continous catheter analgesia of the sciatic nerve
- Use of nerve locator is very useful as the nerve is deeply placed.

ANTERIOR APPROACH

Position: Supine with leg in a slightly abducted position

Site of Needle Entry

Line I: From anterior superior iliac spine to pubic tubercle

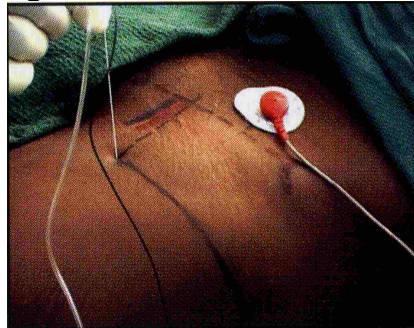


Line II: From mid point of the greater trochanter parallel to L I over the anterior aspect of

the thigh

Line III: Trisect the first line and draw a perpendicular line from the junction of medial 1/3 and lateral 2/3 to join the second line.

Technique: A 12 or 15cm needle is inserted perpendicular to the skin. At about 5 to 6 cm it contacts the femur. The needle is withdrawn and directed medially and if necessary little cephalad to locate the sciatic nerve. About 4cms past the femur, parasthesia or motor response is elicited. Inversion/eversion of foot or dorsiflexion / plantar flexion of ankle is the motor response obtained, depending on whether the tibial or common peroneal is stimulated.



Volume: 15ml

Pearls:

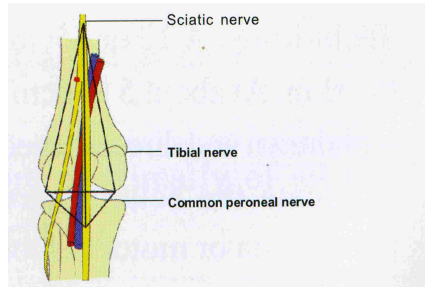
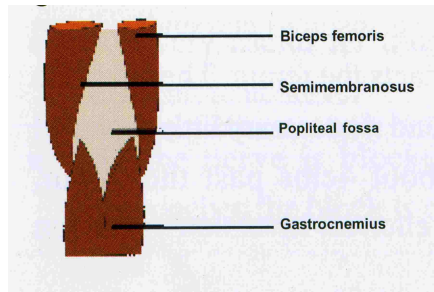
- Very useful in trauma patients
- The site of block of the nerve is lower down than the classical approach and the block may not be complete always.

POPLITEAL BLOCK

Involves blocking the sciatic nerve in the popliteal fossa. Useful block in foot and ankle surgery. Combined with saphenous nerve block for full analgesia of the foot and ankle.

Anatomy:

The popliteal fossa is a quadrilateral space behind the knee joint. It is formed cephalically by Semimembranosus and Semitendinosus muscles medially and biceps femoris laterally. Caudally it is bound on both sides by the heads of the gastrocnemius.

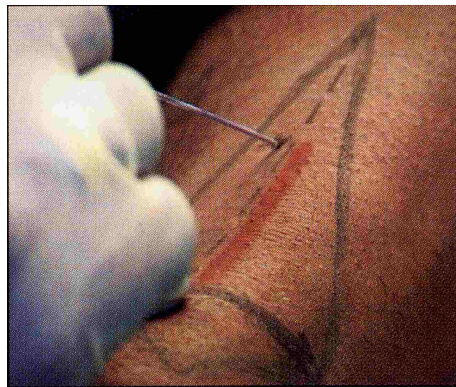


The part of the popliteal fossa above the knee joint can be separated into a triangle by drawing a line over the skin crease. This triangle is further divided into two equal quadrants by a perpendicular line drawn from the apex of the fossa to the skin crease. The lateral quadrant is of importance as the nerve lies here. The popliteal artery is in the medial quadrant. After coursing for 3cm in the fossa, the nerve divides into a tibial and common peroneal nerves.

Position – Prone

Site of Needle Entry:- A point 5cms above the popliteal skin crease and 1 cm lateral to the line bifurcating the popliteal fossa.

Technique: A 7.5cm needle is preferred. It is advanced at an angle of 45 degree to 60 degree to the skin in a cephalad direction. At a depth of 3.5 to 5cm parasthesia or motor response is elicited and drug is injected. It is advisable to have a tibial motor response of plantar flexion and foot inversion.



Volume – 30ml

Pearls:

- Continuous catheters can be placed here
- The nerve is blocked close to the apex of the fossa before its division
- Not very useful in trauma because of prone positioning

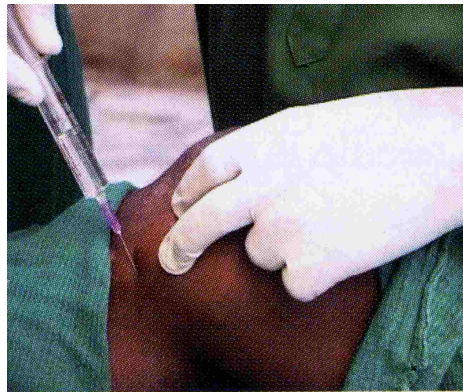SAPHENOUS NERVE BLOCK

Not used in isolation. Very often combined with sciatic nerve block for complete analgesia of ankle and foot. It is a branch of the posterior division of the femoral nerve.

Anatomy

It becomes superficial by piercing the deep fascia between the gracilis and sartorius muscle to run in front of the great saphenous vein.

Position: Patient supine and knee bent to 45 degree



Technique:

A sausage of local anaesthetic is injected just distal to the medial surface of the tibial tuberosity in the subcutaneous plane.

Volume: 5-6ml

Pearls: -Blocking the nerve higher up in the Hunter's canal is also possible. The Hunter's canal is identified by loss of resistance technique.

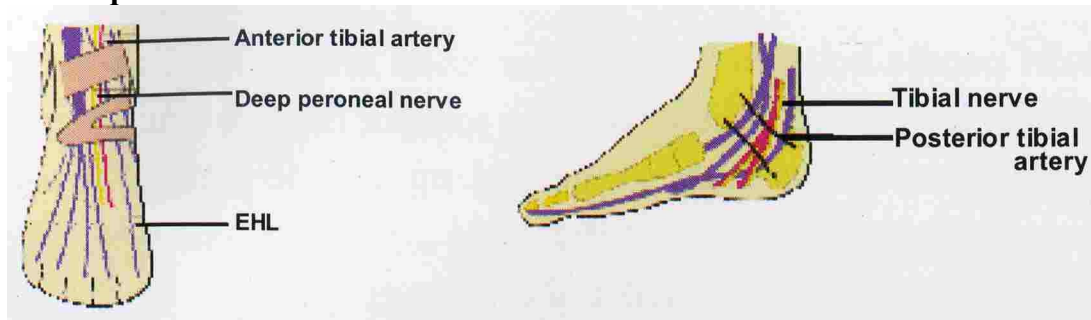
ANKLE BLOCK

Involves blocking the following five nerves around ankle joint

- Posterior tibial nerve
- Sural nerve
- Saphenous nerve
- Deep peroneal nerve

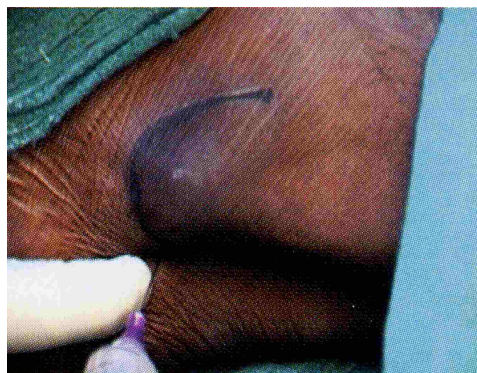-Superficial peroneal nerve

Technique:



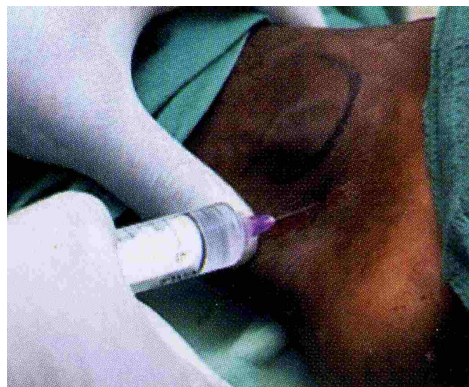
Medial:

The posterior tibial artery is palpated near the medial malleolus. Needle is inserted close to the artery to elicit paresthesia. If it is difficult to elicit paresthesia, advance the needle further to hitch the medial malleolus. Then withdraw by 1cm and give 3-4ml of LA.



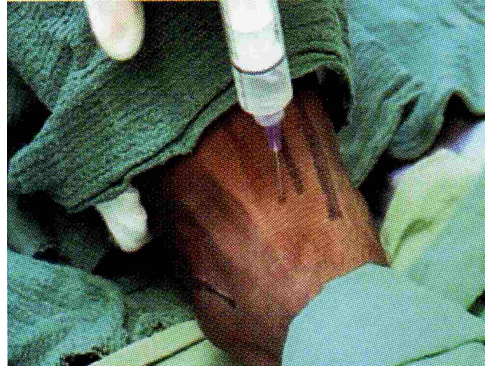Lateral:

The needle is inserted just below the lateral malleolus to elicit paresthesia. If the paresthesia cannot be elicited, hitch the medial malleolus and withdraw by 1.5cm and give 3-4ml of LA.



Dorsal:

Insert needle between the anterior tibial artery and Extensor Halucis Longus tendon on the line joining the two malleolus. Once flexor retinaculum is pierced inject 3 to 4 of local anaesthetic to block the deep peroneal nerve. From this point a subcutaneous weal is raised and drug is given in a medial and lateral direction to block the saphenous and superficial peroneal nerve.

**Pears:**

-As multiple injections are required good sedation is a must for patient cooperation

Conclusion:

These blocks are a very useful tool in the armamentarium of the modern day anesthesiologist. They can be used as a sole anesthetic technique in high risk patients. They are also very useful to relieve acute traumatic, intraoperative and postoperative pain. However to perform these blocks with a high success rate, training in expert hands and a thorough knowledge about the optimal use of nerve locators is a must.



